

# Facial anatomy and the application of fillers and botulinum toxin – Part 2

## *Anatomia da face aplicada aos preenchedores e à toxina botulínica – Parte II*

### ABSTRACT

In part 2 of this review article we will approach the subjects of musculature, vascularization, sensory and motor innervation, and lymphatic drainage of the face. A detailed understanding of these subjects is vital in order to correctly and efficiently apply botulinum toxin and fillers

**Keywords:** anatomy; botulinum toxin type A; injections, intradermal. <sup>1</sup>

### RESUMO

*Na parte II deste artigo de revisão, serão abordadas a musculatura, vascularização, inervação motora e sensitiva e drenagem linfática da face, cujo conhecimento detalhado tem fundamental importância na aplicação correta e eficiente da toxina botulínica e dos preenchedores. <sup>1</sup>*

**Palavras-chave:** anatomia; toxina botulínica tipo A; injeções intradérmicas.

### DESCRIPTION OF THE MAIN MUSCLES OF THE FACE

Next we describe the main muscles of the face,<sup>2</sup> which are key in the detection of wrinkles linked to the muscular dynamics treatable with botulinum toxin (BT), and for estimating the durability and possible displacement of filling substances in the application site.<sup>3-7</sup>

The frontalis muscle is comprised of frontal and occipital portions, and joins the galea aponeurotica. It is anteriorly separated in pairs interlinked by superficial fascia. Since these pairs may either be linked in the middle of the forehead or beyond the hairline, frontal region wrinkles – including its lateral portion – can vary individually (Figure 1). Therefore, a detailed analysis of the patient's musculature and a careful dose calculation is necessary when applying BT. Since the frontalis muscle's function is to elevate the supercilia and produce the

## Educação Médica Continuada



### Author:

Bhertha M. Tamura<sup>1</sup>

<sup>1</sup> PhD in Dermatology from the Universidade de São Paulo (USP) Medical School – São Paulo (SP), Brazil

### Correspondece:

Bhertha M. Tamura  
Rua Ituxi, 58/603 – Saúde  
Cep: 04055-020 – São Paulo – SP, Brazil  
E-mail: bhertha.tamura@uol.com.br

Received on: 20/02/2010  
Approved on: 30/07/2010

Trabalho realizado no Departamento de Biologia e Dermatologia da Universidade Estadual de Londrina - Londrina (PR), Brasil.

Conflicts of interests: none  
Financial support: none

forehead's hyperkinetic wrinkles, its relaxation can influence the shape and position of the eyebrows.

The corrugator muscles originate above the nose, in the internal and anterior portions of the superior and medial orbital margin, joining the frontalis muscle and the eyebrow's skin. Their contraction approximates and pulls the supercilia down, to create glabellar wrinkles (Figure 1). They are closely connected to the orbital septum and, hence, with the levator muscle of the eyelid. This connection is important in the planning the treatment of the orbicular muscle in the upper eyelid, as shown in figure 2. Palpebral ptosis cases are explained by spreading BT in that the treatment of that area with BT.

The procerus muscle originates in the nasal bone, in the glabella, and inserts into the skin of the forehead. The procerus pulls the medial portion of the supercilia down, and is responsible for the transversal wrinkles of the glabellar region (Figure 1). When the procerus is elongated or hypertrophic, it also contributes to the formation of nasal transversal wrinkles – the treatment of which poses a challenge, especially when they have already become permanent.<sup>8</sup>

The orbicularis muscle of the eye originates from the palpebral and orbital ligaments (Figures 3 and 4), merging with the transversal portions of the nasal muscles. It is a circular muscle that acts as a sphincter. Its lateral portion depresses the supercilium. It is important to note that in addition to being respon-

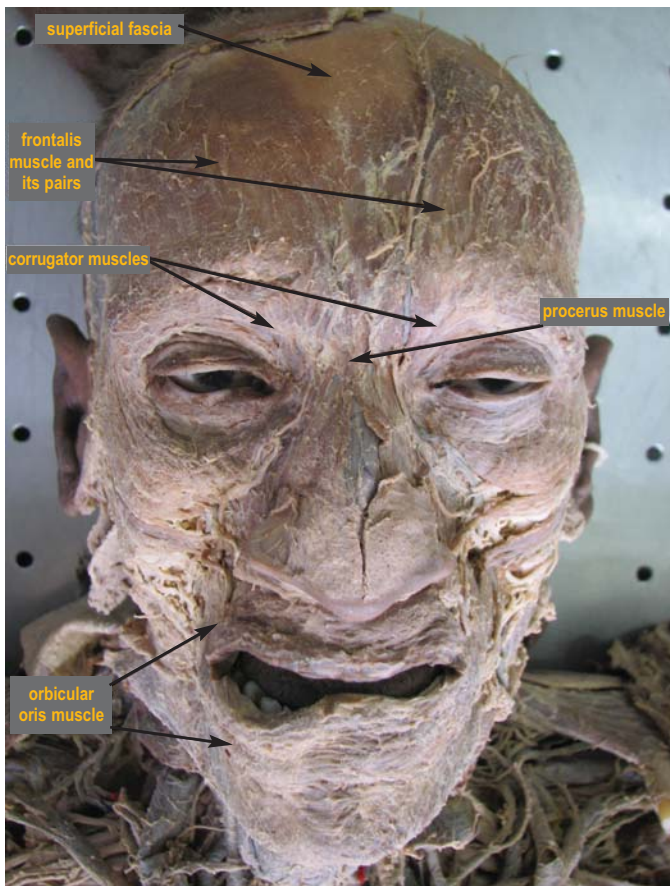


Figure 1: Facial mimicry musculature's general aspect

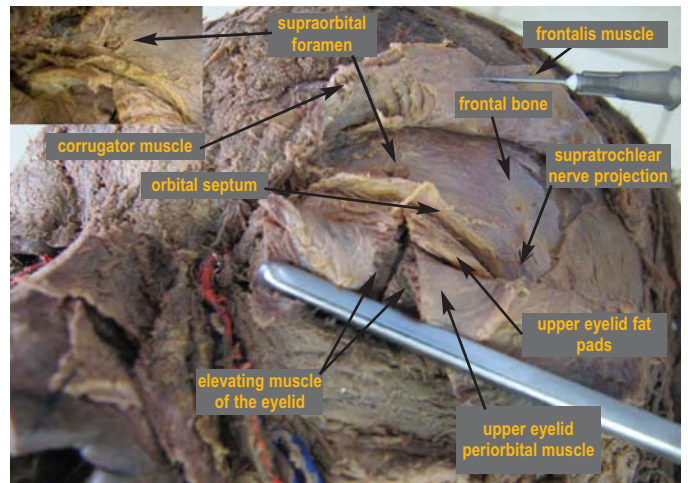
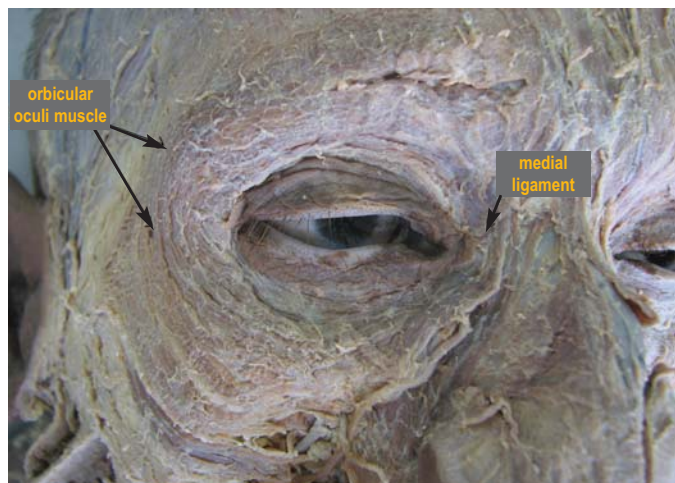


Figure 2: Palpebral region's anatomic details

sible for closing the eyelids, this muscle can cause wrinkles inferiorly, up beyond the zygomatic arch, above the brows, and in the nasal region. The orbicularis muscle of the eye can be extensive in some patients, reaching beyond the brow and covering the malar region, possibly forming long wrinkles that can reach the inferior temporal region. The behavior of sphincter muscles is different from that of the other muscles that generate facial expressions. The localized punctual injection of BT does not relax the entire muscle; it relaxes only the portion being treated, which has a diameter of approximately 1 cm. In this manner, the BT injections should cover the whole area to be relaxed, always bearing in mind that excessive treatment in that muscle can bring about a protrusion of the periocular fat, causing the formation of pads, palpebral edema due to insufficient lymphatic drainage, and ocular dryness due to lachrymal gland alteration.

The upper eyelid's levator muscle (Figure 2) originates in the orbital surface of the small wing of the sphenoid, above and anteriorly to the optic canal, inserting in the eyelid's skin, in the tarsal plaque and in the orbital walls.<sup>8</sup> It is innervated by the oculomotor muscle. Müller's muscle, rudimentary and smooth, is controlled by the sympathetic nervous system and crosses the infraorbital crease and the sphenomaxillary fissure, closely united to the orbit periosteum. The migration or injection of BT in great amounts or at the wrong point in that area can lead to the relaxation of the eyelid levator muscle and cause palpebral ptosis. The risk zones are in the glabella's musculature – especially the tail, the superior portion of the orbicularis muscle of the eye, the area below the brow line, and the upper eyelid in all its extension (because that muscle's fibers insert in the upper eyelid's dermis). When using a collyrium that stimulates the adrenergic system (e.g.: containing adrenaline) or acts on prostaglandins, the Müller's muscle is stimulated, helping to elevate the eyelid by 1-2 mm, in an attempt to partially compensate the action of the eyelid levator muscle, in case palpebral ptosis occurs.



**Figure 3:** Orbicular muscles of the eyes and medial palpebral ligament

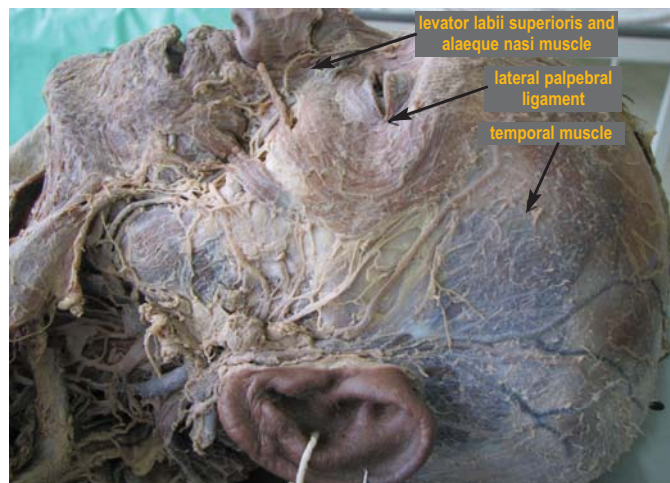The temporal muscle (Figure 4), part of the mastication muscle group, elevates and retracts the mandible. The temporal muscle has two bundles: the superficial bundle (originating in the temporal fossa and fascia) and the deep bundle (originating in the sphenoidal tubercle). The bundles insert in the coronoid process' margins and medial face and in the temporal crest of the mandible. In cases of hypertrophia of the masseter muscle, patients frequently present associated hypertrophia of the temporal muscle, which requires treatment with BT to lengthen and soften the facial outline.

In the infratemporal region we also should consider the lateral (superior and inferior bundle) and medial pterygoideus muscles, which also belong in the mastication muscle group. They are rarely the focus of dermatologic treatments, and are primarily linked to surgical procedures.

The following muscles are found in the infraorbital, zygomatic and cheek regions. The orbicularis muscle of the eye (inferior orbital portion) closes the eyelids and presses them against the eye. It arises in the lachrymal bone, frontal process of the maxilla and the skin surrounding the orbit. The levator labii superioris alaeque nasi muscle (lifter muscle of the upper lip and of the ala nasal (Figure 4) is responsible for the elevation of the upper lip and ala nasal, taking part in the dilatation of the nostrils. It arises in the frontal process of the maxilla and inserts in the ala nasal and upper lip. It is important when treating gingival smile with BT and when aiming at softening the nasolabial fold. The injection must always be applied medially to an imaginary line, lateral to the ala nasal.

The levator labii superioris muscle, as suggested by its name, lifts the upper lip. It arises in the infraorbital margin, inserting in the upper lip. Its relaxation is desirable when treating the gingival smile; inadequate doses can, however, cause serious effects and prevent the lifting of the upper lip.

The zygomaticus minor muscle pulls the upper lip superoposteriorly. It arises in the zygomatic bone and inserts in the upper lip. The zygomaticus major muscle (Figure 5) pulls the angle of the mouth superoposteriorly, arising in the temporal



**Figure 4:** Facial nerve; lifter of the upper lip and of the ala nasal, and temporal muscles; and lateral palpebral ligament

process of the zygomatic and inserting in the angle of the mouth. The risorius muscle slightly pulls the angle of the mouth anteriorly, arising in the parotid-masseteric fascia and inserting in the angle of the mouth. Both the zygomatic and risorius muscles can be relaxed with BT to soften the nasolabial fold and the wrinkles that are located from the external corner of the eyes to the external corner of the lips' lateral region. Treatment in these muscles will cause changes in the patient's smile and that whole area's facial expressions.

The levator angulis oris muscle is responsible for elevating the angle of the mouth (Figure 6). It arises in the canine fossa of the maxilla and inserts in the angle of the mouth. The platysma muscle distends the skin of the neck, pulling it lateroinferiorly, together with the angle of the mouth. It arises in the sternoclavicular joint, clavicle, and scapula acromion, inserting in the base of the mandible – with some fibers inserting in the angle of the mouth. With a strong anterior portion, this muscle extends in the anterior region of the chin towards the lip, reaching the modiolus chiasma. In some individuals, the platysma can also reach laterally up to the mandible's angle; when shaping the contour of the face, it is necessary to conduct a thorough evaluation of the platysma's extension and location before administering any injections.

The buccinator muscle arises posteriorly to the pterygomandibular raphe, and is responsible for the lateroposterior traction of the angle of the mouth and maintaining tension in the cheek during mastication, suction and blowing. The buccinator muscle is located posteriorly to the buccal fat pad, reaching anteriorly to the orbicular oris muscle. This muscle is not usually treated in cosmetic procedures; it is mainly relevant in dermatologic surgery.

The masseter muscle (Figures 5 and 6) belongs in the mastication muscle group. It is located in the parotid-masseteric region and includes a superficial and a deep portion. The superficial portion is located in the anterior two-thirds of the lower border of the zygomatic arch, while the deep portion is found in the internal surface of the posterior third of the lower border



of the zygomatic arch. The first inserts in the mandible's whole lateral branch, functioning as an elevator of the latter. The masseter muscle is considered the strongest in the human body, and the treatment of its hypertrophy is included in dermatologic procedures – in pathological situations and for softening the facial contour. When performing deep injections in this facial region, the parotid duct should also be taken into consideration.

The nasalis muscle (responsible for dilating the nostril) inserts in the ala nasal and the nasalis transverse muscle dilates the nostrils (Figure 7). The depressor muscle of the nasal septum (depressor septi nasi muscle) (Figure 8) shortens the upper lip and lowers the tip of the nose during a smile. Nasal wrinkles are treated with BT in the nasal muscle. In some cases of treatment of the transverse muscle, the opening movement of the ala nasal can be minimized. There are also unconfirmed reports that injecting fillers into the area of this muscle can limit snoring.

The orbicularis oris muscle (Figures 5 and 8) is located in the lip region and surrounds the buccal orifice. The orbicularis oris muscle behaves like a sphincter, and BT can be applied in the upper and lower lip regions. Its extremely superficial location is noteworthy, with insertion in the skin and mucous membrane of the lips. Deep injections of BT should be avoided in this area, since circumoral muscles – closely associated to the orbicularis of the mouth – are also located here. These muscles are responsible for lifting, lowering and retracting the lips, and performing complex movements during normal functioning. From the medial to the lateral position, the lifter muscles of the lip region include: the levator labii superioris alaeque nasi muscles, the levator labii superioris muscle, the minor and major zygomatic muscles, and the risorius. The depressor muscles include: the depressor labii inferioris, the depressor anguli oris and the mentalis muscle.

It is important to note the commissure, due to the fact

that the marionette lines are formed by the depressor muscles of the angle of the mouth (depressor anguli oris muscle) and the platysma. The sagging of the superficial muscular aponeurotic system (SMAS) contributes to the appearance of such lines in senior patients.

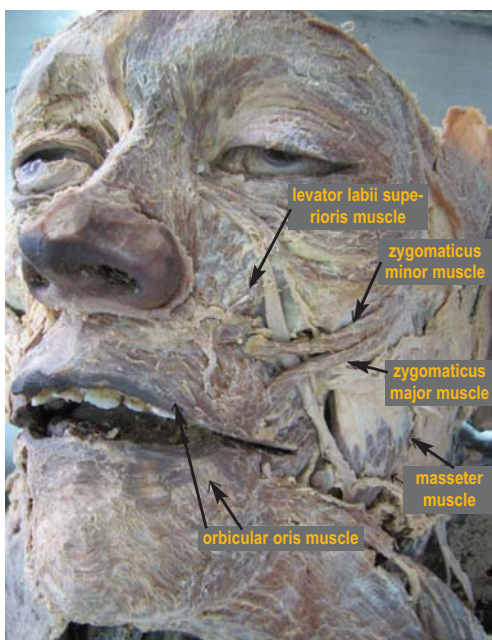
In the chin's muscular layer is the depressor anguli oris muscle, which originates in the mandible basis and inserts in the angle of the mouth. It is the most superficial muscle in that muscle group, and its origin, the most lateral in the mandible. That is the reference point used for injecting BT. The depressor labii inferioris muscle arises in the mandible's base (superiorly to the depressor anguli oris muscle origin) and inserts in the lower lip. The mentalis muscle arises in the mental fossa (superiorly to the mental tubercle) and inserts in the mentum's skin; its function is to wrinkle the mentum skin and invert the lower lip (Figure 9). The contraction of the mentalis muscle causes the lower lip's protrusion. This muscle originates in the mandible, below the central and lateral incisors, and inserts in the mentum's skin. Wrinkles can be formed in the muscle's place of insertion in the skin. If some of its portions are hypertrophied, greater BT doses may be needed, as well as injections in different positions, in order to treat the wrinkles correctly.

#### SENSORY INNERVATION OF THE FACE

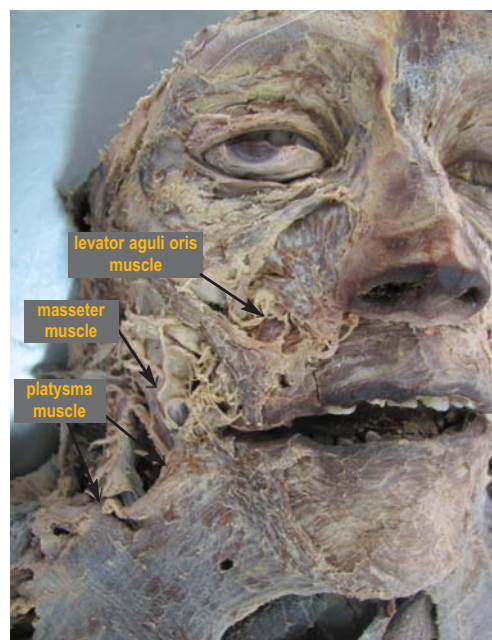
Understanding facial sensory innervation is critical to administering regional anesthesia, especially in areas where filling techniques are used, such as the nose, malar and pre-auricular regions.

#### FOREHEAD


The scalp's frontal and anterior regions are innervated by the supratrochlear and supraorbital nerves (Figures 10 and 11). The supraorbital nerve is responsible for the forehead and scalp's anterolateral portion sensitivity. It emerges in the area between



**Figure 5:** Facial musculature: middle and lower thirds



**Figure 6:** Facial musculature: middle and lower thirds

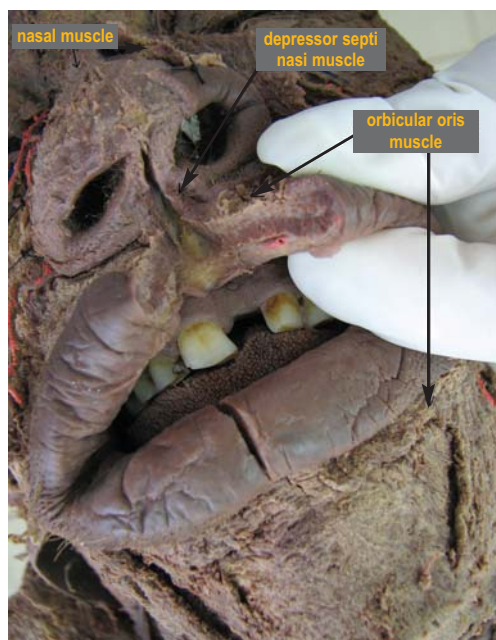

**Figure 7:** Levator labii superioris and alaeque nasi muscles

the medial and central thirds of the superior orbital margin, extending superiorly and laterally on the internal surface of the frontalis muscle and galea.

### EYELIDS

The upper eyelid and the conjunctiva are innervated by the ophthalmic nerve; the cornea, the eyeball, and the cerebellar tentorium's dura mater by the ciliary nerve; the frontal, ethmoid and sphenoid sinuses by the supraorbital and ethmoidal nerves; and the lachrymal gland by the lachrymal nerve. The palpebral branch is located in the superior orbit's lateral region, close to the bone (Figure 12). The lateral regions of the inferior palpebral and conjunctiva, the side of the nose, and nasal vestibule are innervated by the maxillary branch. The infraorbital foramen transmits the infraorbital nerve's terminal branches and the infraorbital artery to the infraorbital region, innervating the



**Figure 8:** Facial musculature, lower third: detail

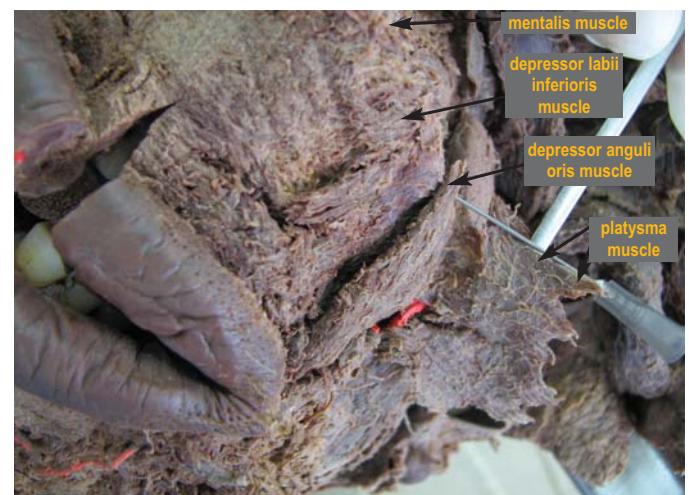lower eyelid and the skin.

### NOSE

The nasal region must be analyzed separately, especially when the procedure's objective involves its sculpture. The dorsum of the nose is innervated by the infratrochlear, dorsal nasal, supraorbital and anterior ethmoidal nerves. The septal and superior nasal mucous membrane are innervated by the anterior ethmoidal nerve. The supratrochlear nerve (a branch of the trigeminal nerve) emerges in the orbit between the periosteum and the orbital septum, in the medial supraorbital margin, innervating the frontal medial and central regions and the nasal root region. On the other hand, the infratrochlear nerve is a branch of the nasociliary nerve (trigeminal nerve), which is responsible for the nasal root's sensitivity. The external nasal nerve is a branch of the anterior ethmoidal (trigeminal nerve), innervating the nasal dorsum, apex and ala. The external portion of the nose is innervated by the infraorbital nerve (located deeply, along the central osseous body of the face), which also has sensory function in the maxillary region.

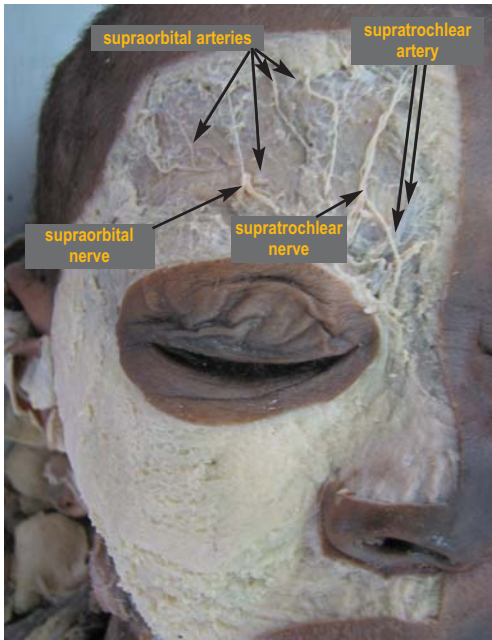
### AURICULOTEMPORAL REGION, CHEEKS, MANDIBLE AND MAXILLA

The auriculotemporal nerve is responsible for the innervation of the auriculotemporal region, the mandible, and the maxilla. It originates in the trigeminal nerve's mandibular branch and extends posteriorly, surrounding the middle meningeal artery. It subsequently follows the shape of the jaw to reach the temporal region in an ascending route, crossing the temporomandibular joint. The external acoustic pore provides sensitive innervation for the temporal region, the temporomandibular joint's capsule, the auricle, the external auditory meatus, the tympanic membrane and the parotid gland. The auricular nerve is in the cervical fascia, posterior to the mandible's angle; the posterior auricular nerve (a branch of the facial nerve) innervates the external acoustic meatus' skin and auricle; and the great auricular nerve's terminals

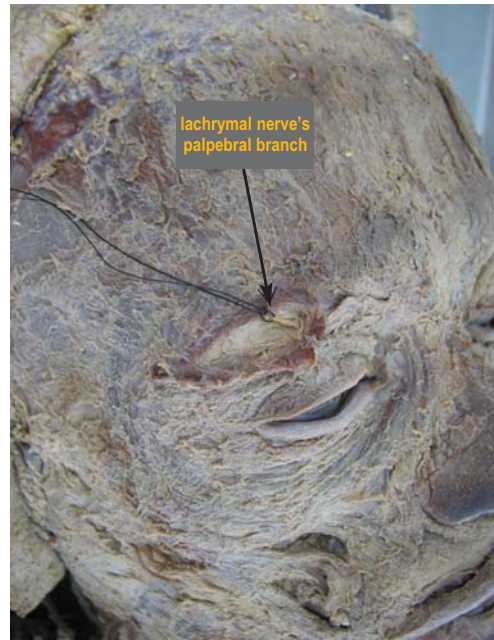

**Figure 9:** Facial musculature, lower third: detail

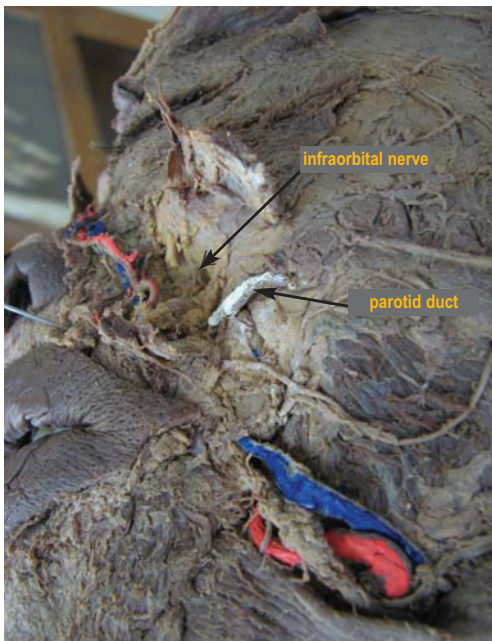




**Figure 10:**  
Anatomic details  
of the face



**Figure 12:**  
Anatomic details  
of the face



**Figure 11:**  
Anatomic details  
of the face

innervate the skin that covers the parotid gland. The tympanic cord's nerve is a branch of the facial nerve that arises in that region through the petrotympanic fissure. The zygomaticofacial nerve (trigeminal nerve's branch) – also arising through the petrotympanic fissure – innervates the skin of the zygomatic region. Finally, the mandibular branch of the facial nerve that passes anteriorly to the medial portion of the mandible is usually located in the angle of the mandible, in the middle lateral zone.

The pterygopalatine and nasopalatine nerves complement the maxillary region's areas. The optic ganglion – located in the medial face of the mandibular nerve's trunk, close to the oval foramen – is responsible for the parotid gland's parasympathetic innervation.

## BUCCAL REGION

Not only the buccal, peribuccal and cheek innervations should be studied, but also those of the internal area of the mouth and the alveoli, due to their close functional relationship. The buccal nerve is one of the trigeminal mandibular nerve's branches that crosses the cheeks' fat pad, after crossing the infratemporal fossa. It is responsible for the cheek's mucous membrane and skin, and the vestibular mucous membrane sensitivity of the inferior molars.

The infraorbital nerve's terminal branches (superior labial) are responsible for innervating the upper lip's mucous membrane and skin, while the mentum branch (which emerges from the mental foramen, below the second inferior premolar) innervates the lower lip's skin and mucous membrane, and the whole mentum region. Its mandibular branch has sensory (sensory branch) and motor (motor branch) functions. The lower lip's mucous membrane and skin, the mentum, the anterior portion of the tongue, and the floor of the mouth are innervated by the mental and lingual nerves. The buccal mucous membrane and the skin of the cheeks are innervated by the buccal and auriculotemporal nerves.

The upper incisors and canine teeth, the maxillary sinuses, nasal cavity and gum are innervated by the superior-anterior alveolar branch. The superior premolar and first molar teeth, and the maxillary sinuses, are innervated by the superior-medial alveolar branch. The superior-posterior alveolar branch innervates the molar tooth, the upper molar region's gums, the buccal mucous membrane and maxillary sinuses. The inferior alveolar nerve arises from the mandibular nerve, continues along the pterygoid muscle's deep lateral face, subsequently continues inferiorly to the branch of the mandible's medial face, penetrates the mandibular foramen, runs through the mandible channel and emits dental branches to the molar and inferior premolar teeth. To important nerves originate in the mental foramen region: the

mental nerve (which innervates the soft tissues of the mentum, mandible and lower lip, as well as the vestibular gum of the incisors, canines and lower premolars) and the mandibular incisive nerve (which innervates the incisor and canine teeth and respective periodontia), running anteriorly and inferiorly, in the medial direction, towards the inferior alveolar nerve. Its fibers follow and are distributed alongside the lingual nerve. It has afferent gustatory fibers (originally from the lingual papillae of the tongue's two anterior thirds) and efferent visceral parasympathetic fibers for the submandibular, sublingual and lingual glands.

The lingual nerve arises in the mandibular nerve, runs anteromedially to the inferior alveolar nerve and passes between the medial and lateral pterygoid muscles. In the posterior extremity of the mylohyoid line, it follows the direction of the oral cavity. The lingual nerve is responsible for the general sensitivity of the tongue's two anterior thirds, the sublingual mucous membrane, the lower teeth's lingual gum, and the submandibular and sublingual salivary glands.

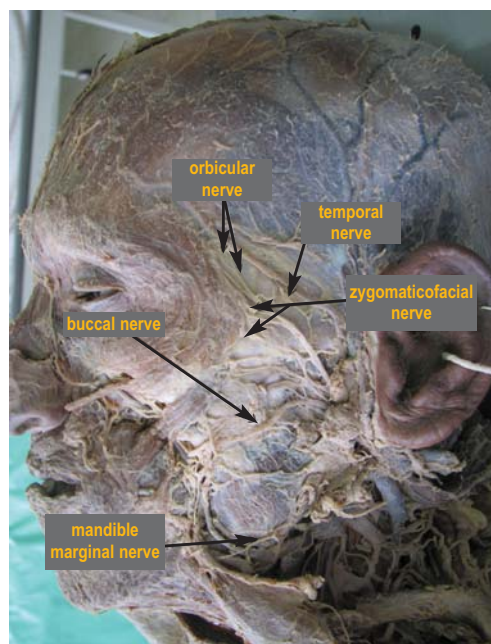
### MOTOR INNERVATION (FACIAL NERVE)

When considering dermal fillers and BT, the motor innervation of the face must be studied in order to avoid possible complications, especially rupture or local trauma. It is worth bearing in mind that BT does not affect nerves, but rather neuromuscular plaques – which is extremely interesting when studying dermatologic surgery and BT's actions. The motor innervation of the face takes place via the facial nerve and its branches.

The temporal nerve (Figure 13) leaves the parotid and crosses the zygomatic arch (middle portion), where it becomes superficial. It is located very superficially in the subcutaneous, along the SMAS, where it is at the greatest risk for traumas or irreversible lesions in small procedures. It innervates the brow, forehead and eyelid regions. It also innervates the anterior and superior auricular muscles, and the epicranium muscle's frontal belly. The subcutaneous or deep temporal fascia plane offers the safest option for dissection and for invasive procedures. The deep anterior and posterior temporal nerves are responsible for the temporal muscle's motor innervation, with the posterior receiving the temporomandibular joint capsule's proprioception.

The facial nerve's frontal branches are located inside the temporoparietal fascia, in the zygomatic arch's middle portion, above its insertion in the frontalis muscle. They are responsible for the motor innervation of the frontalis muscles, corrugators, procerus and the cephalic portion of the orbicularis oculi muscle.

The infratemporal area nerves are: the masseteric, deep temporal, buccal, inferior alveolar, lingual, auriculotemporal, tympanic cord and optic ganglion. The mandibular nerve originates the buccal nerve, which runs laterally among the lateral pterygoid muscle bundles and continues anteroinferiorly and medially up to the temporal muscle's deep fiber bundle. It then crosses the cheek's fat pad and distributes its fibers to the cheek's mucous membrane and skin, and the vestibular gum of the lower molars (and sometimes the upper molars). The inferior alveolar nerve runs downwards, passing close to the lateral pterygoid muscle's deep region and, subsequently, between the



**Figure 13:** Motor innervation of the face

medial and lateral pterygoid muscles. This nerve descends inferiorly in the mandible branch's medial region, enters the mandibular foramen, crosses the mandibular canal and is divided into two dental branches (the molar and the lower premolar branches). After crossing the mental foramen, two important nerves originate: the mental nerve (which innervates the soft tissues of the mentum and lower lip, the incisors' vestibular gum, and the canine and lower premolar teeth) and the mandibular incisive nerve (which innervates the incisor teeth, canine and respective periodontia).

The facial nerve's zygomatic and buccal branches are in the medial and more superficial part of the cheek. The zygomatic nerve innervates the orbicularis oculi muscle's inferior bundle and the buccal nerve (Figure 13), which are responsible for the innervation of the nasal region's upper lip and ala nasal lifter muscles, procerus, risorius, buccinator, orbicularis oris (upper portion), and the alar and transversal nasal muscles. It is also worth noting that this nerve runs slightly more superficially in the zygomatic arch, and that larger amounts of BT must be injected carefully in that area, closely observing and tracking any patient complaint of local paresthesia.<sup>9-11</sup>

The parotideomasseteric region's motor nerves are the facial nerve's terminal branches that emerge from the intraparotid plexus (temporal, zygomatic, buccal, mandible's marginal branches and neck branch). The posterior auricular nerve innervates the occipitofrontal and posterior auricular muscles' occipital belly; the stylohyoid branch innervates the stylohyoid muscle; and the digastric branch innervates the digastric muscle's posterior belly.

The pterygopalatine region's nerves that must be remembered are the infraorbital, zygomatic, posterior superior alveolar, pterygopalatine, nasopalatine, and pterygopalatine ganglion.

The buccal branches are the upper lip muscles' motor nerves, while the mandible marginal branch performs the same



function in the lower lip. They are considered to be high-risk nerves regarding traumas and complications in thin patients. The upper lip's sensory innervation is provided by the infraorbital nerve, while that of the lower lip is provided by the mental nerve as previously described, with their nerves emerging from the infraorbital foramina and mental foramen. The buccal branches are responsible for the orbicularis oris muscle motor innervation; the muscles that surround the mouth are innervated by the buccal and mandible marginal branches (Figure 13). In this way, as in the case of the zygomatic and facial nerves, greater care should be taken when injecting substances at a 2 cm distance from the lateral angle of the mouth, where the nerve is more exposed and prone to trauma.<sup>11-13</sup>

The marginal mandibular nerve (originating in the facial nerve) is responsible for the motor innervation of the muscles of that region and runs through the parotidomasseteric region and cheek. The mandible's marginal nerve is located deeply in the platysma muscle, up to 4 cm beneath the mandible's inferior border. However, as it approaches the mouth it assumes a superficial direction and penetrates the depressor muscle. A trauma in that muscle causes an inability to depress the mouth. The buccal branch runs up to the buccinator muscle, and a lesion in the branch that ends in the orbicularis oris muscle leads to the impairment of the capacity to elevate the angle of the mouth.

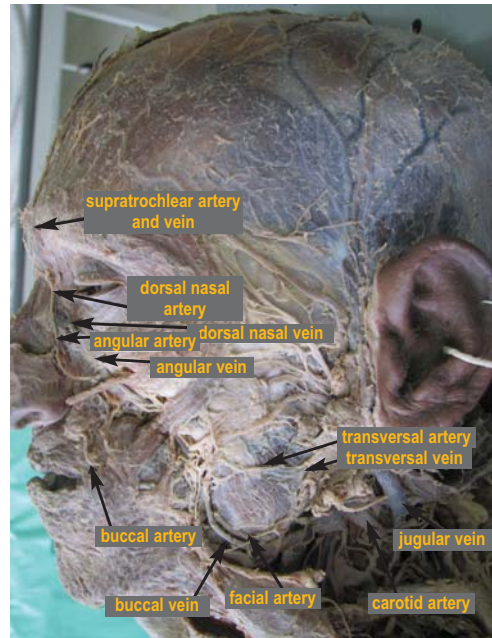
## FACIAL BLOOD SUPPLY

Currently, when studying vessels, attention must be primarily focused on reports of arterial occlusion – in some cases with very serious complications related to the injection of fillers. Therefore, when treating a patient with BT, not only the muscles but also the arterial system must be fully understood by the dermatologist who practices facial sculpture with fillers.

The external carotid artery's main function is the irrigation of the face. Its main branches are the thyroid, the lingual, the facial (Figure 14), the occipital, the posterior auricular, the maxillary and the superficial temporal arteries.

The facial artery and its branches are the most studied, however others are also important and will likewise be discussed. This artery's route follows the mandible's external surface, beneath the platysma up to the internal corner of the eye. It crosses the buccinator muscle and the maxilla, deeply to the zygomatic major and elevator of the upper lip muscles. The facial artery sends branches to the lip and the nostril's lateral face. The angular artery is the portion of the facial artery that runs along the nose up to the internal angle of the eye to supply the eyelids.

The external carotid's largest branch is the maxillary artery, which divides into a deep auricular section (with branches to the external auditory meatus), a tympanic section (with branches to the tympanic membrane), the meningeal artery and the alveolar artery (with branches for the gums and teeth). The masseteric, deep temporal, pterygoid and buccal branches originate in the second largest branch. The third branch in turn separates into the supero-posterior alveolar, medium superior alveolar, infraorbital, descendant palatine, pterygoid canal, pharyngeal and sphenopalatine arteries.



**Figure 14:** Artery and vein irrigation of the face

The superficial temporal artery is a terminal branch of the external carotid artery. It arises in the parotid gland and runs up in a superficial plane towards the posterior portion of the temporal bone's zygomatic process up to the mandible's body. It ascends and crosses anteriorly to the external acoustic pore; terminal branches originate 2-3 cm above the zygomatic arch. It irrigates the temporal, frontal and parietal regions, the parotid gland and its duct through branches with similar names. The main vein in the temporal region is the superficial temporal vein. It drains the temporal, frontal and parietal regions. The lateral and medial pterygoid muscles are irrigated by the posterior deep temporal artery. This region's main vein is the retro-mandibular vein (maxillary and superficial temporal vein) that is located close to the mandible's body, descending through the parotid gland's interior. In the temporal region, veins are tributary to the pterygoid plexus.

When filling the pretragal region, injections should be delicate and slow in the subcutaneous deep plane, perpendicular to the superficial temporal artery. To prevent serious traumas, the needle must not be introduced repeatedly in the same place. Moreover, the pressure of injecting large volumes into this area can cause paresthesia and thus must be avoided.<sup>13</sup>

The infratemporal region is irrigated by the middle meningeal artery, anterior and posterior deep temporal, superior posterior and inferior alveolar, infraorbital, masseteric, mylohyoid, buccal and lingual arteries. The middle meningeal artery irrigates the dura mater and the adjacent bone. The superior posterior alveolar artery penetrates the maxillary tuberosity through the alveolar foramina irrigating the molar and superior premolar teeth through dental branches, and the alveolar process, periodontium and vestibular gum through periodontal branches. The posterior inferior alveolar artery arises in the same region of the middle meningeal artery, however runs towards the mandibular foramen. Before penetrating the mandible channel, the posterior



inferior alveolar artery ramifies into the mylohyoid artery, which irrigates the mylohyoid muscles and the digastric muscle's anterior belly. The infraorbital artery originates in the pterygomaxillary fissure (close to the maxillary tuberosity), and penetrates the orbit and exits in the face through the infraorbital foramen. Its terminal branches irrigate the soft tissues in the middle third of the face (lower eyelid), external nose and upper lip. The masseteric artery arises in the lateral pterygoid muscle region, passing laterally through the mandibular incisura, where it irrigates the masseter muscle and the temporomandibular joint capsule.<sup>14</sup>

The buccal artery arises close to the anterior deep temporal artery, following a latero-inferior route to the jugal region, irrigating the cheek and the buccinator muscle. The lingual artery (originating in the external carotid artery) runs towards the hyoglossus muscle to ramify and irrigate the tongue's muscles, the postsulcal part of the dorsum of the tongue, the floor of the mouth and the sublingual gland. The infratemporal region's veins constitute the pterygoid venous plexus, which receives the blood from the face's deep region, draining it to the maxillary veins. The labial arteries of the upper and lower lips are disposed exactly in the place where the fillings are injected: between the upper and lower lip's wet and dry mucous membrane line and in the internal part of the upper lip.<sup>15</sup>

The supraorbital artery is a terminal branch of the ophthalmic artery that arises from the internal carotid artery. In the infraorbital, zygomatic and cheek regions, the lachrymal artery branch becomes external in the lateral region of the orbit and anastomoses with the transverse facial artery (superficial temporal artery's first branch). The transverse facial artery arises from the superficial temporal artery before emerging from the parotid gland, and crosses the face superficially to the masseter muscle. It then divides into several branches that supply the parotid gland, its duct, the masseter muscle and the skin of the face. There are also terminal infraorbital artery branches (inferior palpebral, superior and nasal labial) that arise from the infraorbital foramen. The facial, buccal and anterior superior alveolar arteries' branches also help irrigate that region. The veins are tributaries of the facial, temporal superficial and pterygoid plexus. The maxilla region's supero-external portion has a deep venous compound that must be avoided when injecting fillers.

The external carotid artery is the parotideomasseteric region's main artery. It runs upwards, passing between the styloglossus and stylohyoid muscles, creating the posterior auricular artery, penetrating the parotid gland. In the mandible's body, it gives off the terminal branches of the temporal and maxillary artery.

The lips and nose are mainly irrigated by the facial artery. Facial arteries are extremely tortuous and the most modern filling technique for obtaining natural lip enhancement – in various planes and directions – inevitably causes the perforation of arteries, with greater probability of hematomas and ecchymosis. The angular artery is a terminal branch of the facial artery that irrigates the lateral region of the dorsum of the nose close to the root, crosses the lifter muscle of the upper lip and of the ala nasal. Due to its characteristics and the size of the area

that it irrigates, occlusion of the angular artery (resulting from injection, spasm, or compression) can lead to necrosis, ischemia and scars in the whole area that is dependent on it. The columella and lateral nasal artery branches irrigate the ala, dorsum, and tip of the nose. The dorsal nasal artery irrigates the nose's root and dorsum. One of its branches joins the angular artery in the root of the nose, while the other descends, anastomosing with the external nasal artery (a branch of the infraorbital artery). The lateral nasal veins are located 2–3 mm from the alar crease. They appear deeply in the nasal base with the columellar artery and end in the subdermal plexus's tip. They are tributaries of the angular vein, which supplies the entire external nose.

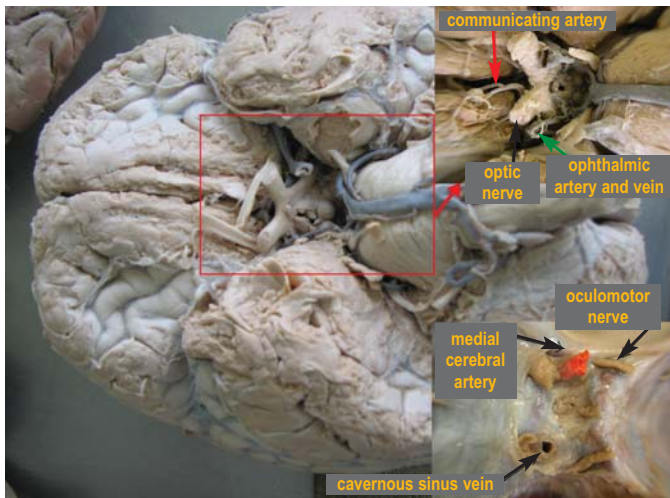
The lips are irrigated by the superior and inferior labial arteries (branches of the facial artery), which anastomose with those on the opposite side of the face, forming an arterial circle around the vermilion border.

In the mentum region, the most important arteries are the submental and mental. The submental arteries originate from the facial artery in the submandibular region, pass by the mandible's base up to the mentum, and irrigate the mylohyoid muscle, the digastric muscle's anterior belly and adjacent structures. The mentum is also supplied by the mental artery – a branch of the inferior alveolar artery that emerges through the mental foramen. The venous drainage corresponds to the arterial supply. The mandible is supplied by the facial and inferior alveolar arteries.

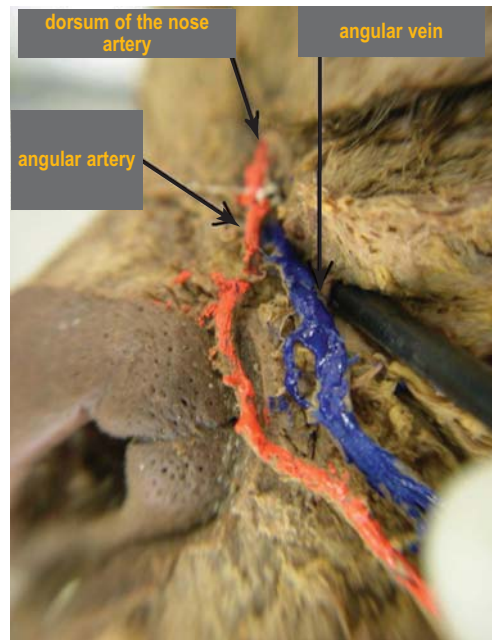
## BLOOD SUPPLY OF THE RETINA

The central artery of the retina is a branch of the ophthalmic artery, mainly arising from the internal carotid artery. The central artery passes in the optic nerve and disc, and is separated into temporal superior and inferior branches, and nasal superior and inferior branches. Although it anastomoses with the ciliary arteries, the branches described do not anastomose either amongst themselves or with any other vessels, and are therefore functionally regarded as a terminal artery (without communication between arterioles and venules); connections only happen through the capillary network. The occlusion of the central artery results in blindness. The retina's veins follow the arteries, ending in the cavernous sinuses (Figure 15). With several cases of amaurosis described in the literature some studies attempt to explain the etiopathogenesis of the occlusion of the central artery following the injection of fillers in the glabellar region. The inversion of the flow or the anastomoses between arterial vessels of the internal carotid with those of the external carotid at that level can explain that complication. It is advised to avoid injecting filling products in this region until this complication is completely understood; however it is important to bear in mind that thrombi can lead to blindness following the intra-arterial injection of thick periocular implants.<sup>8,14</sup>

Additionally, there are reports verifying anastomosis in the intranasal region, between the internal and external carotid arteries, with the possibility of blindness as in the ophthalmic region. Nevertheless, vascular occlusion and amaurosis continue



**Figure 15:** Periorbital area irrigation aspects



**Figure 16:** Periorbital area irrigation aspects

to be discussed.

The palpebral veins flow to the angular (Figure 16), ophthalmic and superficial temporal veins. The angular and ophthalmic veins' anastomosis allows communication between the palpebral medial and lateral nasal regions and the cavernous sinuses, where there is a possibility of intracranial infection. That is one of the contraindications in the inadequate drainage of infected skin lesions (and without the administration of antibiotics), as well as the injection of corticosteroids or substances for vascular sclerosis, in the periorbital and central facial regions.

## LYMPHATIC SYSTEM

The drainage of the face occurs in the posterior and inferior directions, with the medial region (including the upper and lower lips) draining to the facial, submental (including the lower lip's central region), and sub-mandibular lymph nodes. The facial lateral region, scalp and frontal area drain to the diagonal line (infraorbital, zygomatic and cheek region) up to the parotid lymph node. In practice, in cosmetologic dermatology and in physiotherapy and aesthetics studies, drainage problems in the periocular region are very frequent. For instance, patient complaints (caused by a technical reason) about "swelling" in the eyes following the application of BT are very common. When large volumes of fillers are injected in the tear trough or when a periocular sculpture is carried out – or even in surgeries in that area – the appearance of edemas is also common. In fact, the palpebral lymphatic system is very delicate and not prepared for traumas or procedures. The periorbital muscles' movement has an important role in the drainage of local fluids. Therefore, when those muscles relax because of the BT treatment, temporary or permanent edema can occur during the whole relaxation period. The alteration of pressure due to a variation in volume also leads to the occlusion of the ducts, which are very

delicate and sensitive. Although lymphatic drainage is usually described within a regional context, advanced studies show that massage (manual or with the aid of equipment), in the medial (– towards the nasal region's drainage system) and lateral (towards the parotids) directions can help patients with lymphatic drainage problems in the eyelid area.

The infratemporal region's lymph vessels drain to the superior deep cervical lymph nodes. The parietal and occipital region of the scalp drains anteriorly to the parotid lymph node, and posteriorly to the retroauricular lymph node. The occipital region drains to the occipital region's lymph node, and the pericervical lymph nodes filter the lymph between the head and neck, scalp and mucous membrane. In the pterygopalatine region, lymphatic drainage flows, basically, to the retropharyngeal and superior cervical deep lymph nodes. ●

## ACKNOWLEDGEMENTS

We would like to thank Dr. Eduardo Rafael de Veiga Neto, Associate Professor C at the Anatomy Department of the Biological Sciences Center of the Universidade Estadual de Londrina (UEL) – Londrina (PR), Brazil; Marco Aurélio Zambon, Laboratory Technician CH 40 at UEL's Anatomy Department; and the UEL Biology and Dermatology Departments for their great support and affection, which made our research possible.



**REFERÊNCIAS**

1. Alam M, Dover JS. Management of complications and sequelae with temporary injectable fillers. *Plast Reconstr Surg.* 2007;120(6Suppl):985-1055.
2. Altruda Filho L, Cândido PL, Larosa PRR, Cardoso EA. Anatomia topográfica da cabeça e do pescoço. Barueri, São Paulo: Manole; 2005.
3. Alam M, Gladstone H, Kramer EM, Murphy JP Jr, Nouri K, Neuhaus IM, et al. ASDS guidelines of Care: injectable fillers. *Dermatol Surg.* 2008;34(Suppl 1):s115-48.
4. André P, Levy P. New trends in face rejuvenation by hyaluronic acid injections. *J Cosmetic Dermatol.* 2008;8(4):251-258.
5. Arletti JP, Trotter MJ. Anatomic location of hyaluronic acid filler material injected into nasolabial fold: a histologic study. *Dermatol Surg.* 2008;34(Suppl 1):s56-63.
6. Carruthers J, Cohen SR, Joseph JH, Narins RS, Rubin M. The science and art of dermal fillers for soft-tissue augmentation. *J Drugs Dermatol.* 2009;8(4):335-50.
7. De Figueiredo JC, Naufal RR, Zampar AG, Mélega JM. Expanded median forehead flap and Abbé flap for nasal and upper lip reconstruction after complications of polymethylmethacrylate. *Aesthetic Plast Surg.* 2010;34(3): 385-7.
8. Gardner E, Gray DJ, O'Rahilly R. Anatomia. 4. ed. Rio de Janeiro: Guanabara Koogan; 1978.
9. Glogau RG, Kane MAC. Effect of injection techniques on the rate of local adverse events in patients implanted with nonanimal hyaluronic acid gel dermal fillers. *Dermatol Surg.* 2008;34(Suppl 1):s105-9.
10. Goldberg DJ. Correction of tear trough deformity with novel porcine collagen dermal filler (Dermicol-P35). *Aesthet Surg J.* 2009;29(3 Suppl):s9-11.
11. Goldberg DJ. With this filler/volumizing agent now becoming available, the interest in non-surgical facial sculpturing will continue to expand. *J Cosmet Laser Ther.* 2008;10(3):133.
12. Haddock NT, Saadeh PB, Boutros S, Thorne CH. The tear trough and lid/cheek junction: anatomy and implications for surgical correction. *Plast Reconstr Surg.* 2009;123(4):1332-40; discussion 1341-2.
13. Hirsch RJ, Stier M. Complications of soft tissue augmentation. *J Drugs Dermatol.* 2008;7(9):841-5.
14. Sobotta J, Becher H. Atlas de Anatomia Humana. 17. Ed. Rio de Janeiro: Guanabara Koogan; 1977.
15. Sadick NS, Karcher C, Palmisano L. Facial enhancements using dermal fillers. *Clin Dermatol.* 2009;27: s3-12.